

# Chemical Sphincterotomy Versus Surgical Sphincterotomy in the Management of Chronic Fissure in ANO: A Prospective, Randomized Trial

RITHIN SUVARNA, PANCHAMI, GURUPRASAD RAI D.

## ABSTRACT

**Introduction:** Fissure in ano is a common cause of severe anal pain. The hypertonia and spasm of the internal anal sphincter is believed to be the chief pathology in chronic fissures. The reduction of this hypertonia is most commonly achieved by surgical sphincterotomy, that results in fissure healing in more than 90% of the cases. However, the surgery carries a significant risk of incontinence. In this study, we explored chemical sphincterotomy by using topical 2% diltiazem as an effective and a safe alternative method to the surgical treatment for chronic fissure in ano.

**Materials and Methods:** In this prospective trial, 200 patients with chronic anal fissures were randomly divided into group 1 and group 2, with 100 patients in each group. The group 1 cases received 2% topical diltiazem at the perianal skin twice daily for 6 weeks, while the group 2 subjects underwent lateral

internal sphincterotomy. They were assessed biweekly during the treatment. The follow up was carried out for one year.

**Results:** Complete fissure healing was found in 69.23% patients of group 1 (topical diltiazem) and in 95.87% patients of group 2 (surgical sphincterotomy). In the first group, the pain relief was fairly good, while in group 2, the response was quick and excellent. Mild headache was the main side effect in group 1, while it was anal incontinence in group 2. 10.43% of the cases from the group 1 had recurrence, whereas none in the second group had it.

**Conclusion:** We conclude that chemical sphincterotomy with the use of 2% topical diltiazem may be considered as first line treatment for chronic anal fissure. Surgical sphincterotomy should be reserved for patients who have failed to respond to chemical sphincterotomy.

**Key Words:** Fissure-in-ano, Sphincterotomy, Topical diltiazem

## INTRODUCTION

Fissure in ano (AF) is a common proctologic condition in which there is a linear laceration in the lining of the distal anal canal, which is a common cause of severe anal pain [1].

The pathogenesis of anal fissures is not well understood [2]. Constipation and hard stools have been thought to be the important initiating factors [3]. The chief pathology in chronic fissures appears to be persistent hypertonia and spasm of the internal anal sphincter [4-6]. The reduction of this hypertonia improves the local blood supply and encourages the fissure healing.

Chronic anal fissures, unlike acute fissures, don't usually resolve with simple measures [7]. They are most commonly treated by surgical sphincterotomy that heals the fissures in more than 90% of the cases [7,8]. However, the surgery carries a significant risk of incontinence [9-11]. This limitation of the surgery has led to a search for alternative therapies such as topical diltiazem (chemical sphincterotomy), topical glyceryl trinitrate, etc.

The aim of this prospective randomized trial was to compare the effectiveness and the side effects of chemical sphincterotomy (with the use of topical 2% diltiazem) versus surgical sphincterotomy in the treatment of chronic anal fissures.

## MATERIALS AND METHODS

This prospective, comparative study was undertaken at the Vinaya Hospital and Research Centre, South Canara, from 2009 to 2012.

200 patients with a definite diagnosis of chronic anal fissure were enrolled in this study after obtaining an informed written consent from them. Ethical approval was obtained from the local ethical committee.

The inclusion criteria included the patients who were aged between  $\geq 18$  years and  $\leq 65$  years with chronic anal fissures, who had symptoms for more than 8 weeks that had failed to resolve with simple measures (stool softeners, a high fibre diet and a warm sitz bath) and their physical examination revealed fibrotic fissures with indurations at the edges, external skin tags, and exposure of the horizontal fibres of the internal anal sphincter.

Pregnant/lactating women, patients with anal fissures due to inflammatory bowel disease, those with tuberculosis, malignancy and sexually transmitted diseases; those with prior anal surgery, associated haemorrhoids and fistula and patients with significant cardiovascular conditions were excluded from the study.

The subjects underwent a clinical examination which included a digital rectal and a proctoscopic examination. Sigmoidoscopy and colonoscopy were carried out whenever they were necessary. Of the 200 patients with chronic anal fissures, 100 patients were randomly assigned to group 1, who received treatment as outpatients and the remaining 100 patients were assigned to group 2 (surgical sphincterotomy group). The second group was hospitalized for the surgery.

The first group was treated with a 2% diltiazem ointment (chemical sphincterotomy). The subjects were instructed to apply the ointment (about a size of a pea) to the anal margin by using their tip of the index finger, twice daily for 6 consecutive weeks. The cases from the second group underwent left lateral internal sphincterotomy under spinal/general anaesthesia. During the course of the treatment, both the groups were asked to eat a high fibre diet and to use warm sitz baths.

They were reviewed in the Outpatients Department at the 2nd, 4th and 6th weekends during the course of the treatment and then, bimonthly for a year. At each visit, details on the fissure healing, pain relief and any side effects and recurrence were noted down. Also, specific questions were asked, particularly to the second group, regarding the leakage of flatus and faeces. The healing of the fissure was assessed visually and the intensity of the pain was assessed from a visual analogue score. Healing was defined as the complete disappearance of the fissure on examination. Every patient was supplied with a pain score chart. They were instructed to mark the level of the pain in it daily. These charts were graded from 0 to 10 and they were marked at one end-0 (no pain) and at the other end -10 (worst pain). The disease was considered as recurrent if the fissure reappeared at the same site, 2 months after the surgery or 2 months after the 6 weeks course of the diltiazem application.

The data was collected and analyzed statistically by using the SPSS version17 software. The p values were calculated by using the Chi-square test.

## RESULTS

The clinical details of the 200 cases which were studied have been shown in the [Table/Fig-1].

Features	Group 1 (N=100)	Group 2 (N=100)	P-value
Male	44	53	0.2577
Female	56	47	
Age in years: Range and Mean $\pm$ SD	18-64 40.19 $\pm$ 14.06	18-65 39.58 $\pm$ 13.18	0.752
Duration of symptoms: Range and Mean $\pm$ SD	6-12month 8.17 $\pm$ 1.52	6-10months 8.38 $\pm$ 1.29	0.0995
Symptoms:			
Pain	95	97	0.7182
Bleeding	85	88	0.679
Constipation	49	58	0.257
Co-morbidity:			
Diabetes mellitus	9	11	0.813
Hypertension	6	4	0.7456
Local findings:			
Location:			0.294
Posterior midline AF	79	72	
Anterior midline AF	10	8	
Anterior+ posterior AF	6	8	
Multiple/lateral Fissures	5	12	
Sentinel pile	83(83%)	84 (84%)	
Sphincter spasm	90 (90%)	87 (87%)	

[Table/Fig-1]: Clinical details of the cases

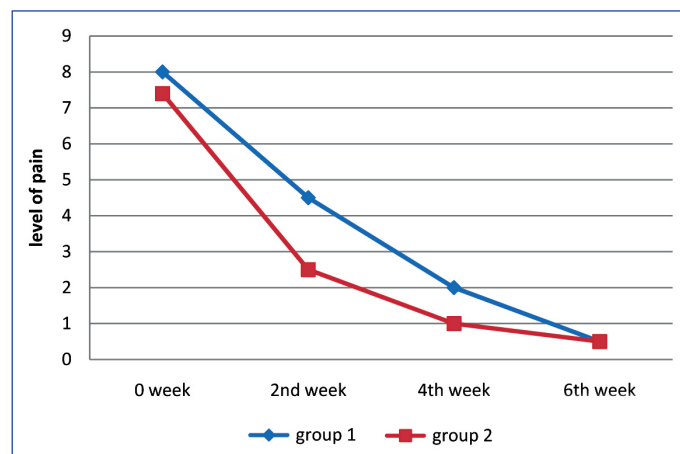
In the first group, there was a slight female predominance, whereas a slight male predominance was observed in second group [Table/Fig-1]. A majority of the cases in both the groups had anal pain and bleeding. A few cases had constipation as well. Diabetes mellitus and hypertension were noted in few patients. The commonest location was the posterior midline [Table/Fig-1]. Most of the cases had sphincter spasms and an external skin tag (sentinel pile).

The cases were evaluated at the 2nd, 4th and 6th weekends for fissure healing, pain alleviation, side effects and recurrences. 9 cases from group 1 and 3 cases from group 2 failed to complete the study due to cooperation problems. These subjects were not considered in the statistical analysis.

Fissure healing	Group 1 (N=91)	Group 2 (N=97)
At 2 <sup>nd</sup> week end	0	0
At 4 <sup>th</sup> week end	56 (61.53%)	55 (56.70%)
At 6 <sup>th</sup> week end	63 (69.23%)	93 (95.87%)

[Table/Fig-2]: Fissure healing

Complete fissure healing was noted in 69.23% patients of group 1 (chemical sphincterotomy) and in 95.87% patients of group 2 (surgical sphincterotomy) within 6 weeks [Table/Fig-2].



[Table/Fig-3]: Pain response in group1 (chemical sphincterotomy) & group 2 (Surgical sphincterotomy)

In the first group, the pain response was fairly good. The pain score (mean) fell steadily over 6 weeks [Table/Fig-3]. But the pain alleviation in the second group was excellent and quick. In the second group, a steep drop in the pain score was noted in the first two weeks [Table/Fig-3].

Side effect	Group 1 (N=91)	Group 2 (N=97)	P-value
Head ache	5	0	<0.0001 (Significant)
Flatus incontinence	0	9	<0.001 (Significant)
Faecal incontinence	0	5	<0.002 (Significant)

[Table/Fig-4]: Adverse Effects of the treatments by 6 week end

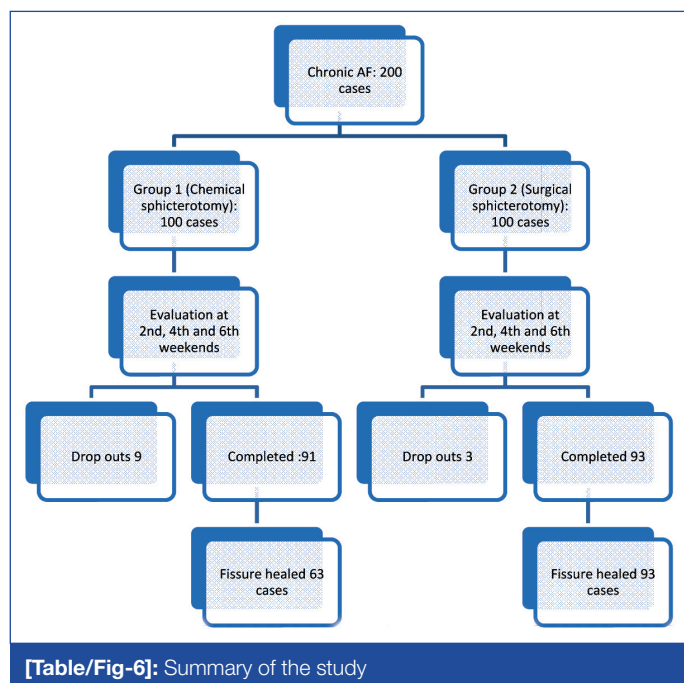
Mild headache was experienced by 5.49% patients of group 1, while none of the patients in group 2 had it. 9.27% of the cases from group 2 complained of flatus incontinence, whereas none of the cases in group 1 had it. However, the flatus incontinence improved over time, so that at the end of the 1 year follow up, only 2 cases still had it. 5.15% cases in group 2 had a frank faecal incontinence in the first 6 weeks. Nevertheless, it also resolved completely over time [Table/Fig-4].

5 of the 63 fissure healers from group 1 and 4 of the 93 healers from group 2 didn't show up for follow up, while the rest of the patients completed the full 1 year's follow up.

	Group1 (N=58)	Group 2 (N=89)
Recurrences	6	0

[Table/Fig-5]: Recurrences

10.43% of the cases from group 1 had recurrence, while none in group 2 had it [Table/Fig-5].



[Table/Fig-6]: Summary of the study

## DISCUSSION

Fissure in ano is a common proctologic disease in which there is a vertical tear in the lining of the distal anal canal [1]. The posterior midline is the commonest location, followed by the anterior midline, especially in females [12] [Table/Fig-6].

The pathogenesis of chronic AFs is poorly understood [2]. Constipation and hard stools are often associated with fissures and they have been believed to initiate fissure formation [3]. Inflammatory bowel disease and tuberculosis may be associated with fissures. In females, they often occur during pregnancy and following delivery [7]. Chronic AFs are associated with internal anal sphincter hypertonia. The reduction of this hypertonia improves the local blood supply, thus encouraging the fissure healing.

A sharp anal pain during defaecation, which is associated with the passage of bright red blood per rectum, is the classical feature of AFs [1]. The pain may be so severe, especially in acute fissures, that the patients may postpone the defaecation for days together until it becomes inevitable [7]. This leads to hardening of the stools, which further worsens the condition.

The fissures can be acute or chronic. Acute fissures have a shorter duration (less than a month) and they have fresh mucosal edges [1]. They usually resolve with the use of simple measures like a high fibre diet, adequate water intake, and warm sitz baths [1].

Chronic fissures are characterized by a sentinel pile, hypertrophic anal papillae, anal spasms and/or fibrosis of the internal sphincter muscle [2]. The internal sphincter fibres are usually exposed on the floor of the well developed fissure which goes into spasm due to irritation [7]. The chronic AFs usually do not heal with simple

conservative measures [7]. They are most commonly treated surgically by lateral internal anal sphincterotomy, which lowers the resting anal pressure and heals them in more than 90% of the cases [7,8]. But, sphincterotomy carries a significant risk of incontinence [8-11]. This drawback of the surgical treatment has led to a search for alternative therapies.

Chemical sphincterotomy has been tried by using a variety of agents which include topical glyceryl trinitrate (GTN), calcium channel blockers such as nifedipine or diltiazem and botulinum toxin. Some of these agents were found to be effective in healing chronic anal fissures with negligible side effects and these are now being considered as the first line treatment for chronic AFs [13]. However, the medical treatment has two limitations: the moderate effectiveness (between 30% and 80%) and the need for a prolonged treatment [10].

Topical GTN has been the most extensively studied and followed non-surgical treatment for chronic anal fissures [8]. Although it is effective, headache and a high recurrence rate are its main drawbacks [1,14-18].

Diltiazem is a calcium channel blocker which acts by blocking the calcium channels in the smooth muscles, thus causing relaxation [1]. Various studies have reported a 60% to 75% fissure healing rate with topical diltiazem [19-22]. Moreover, topical diltiazem causes less headache and a fewer side effects than the GTN ointment [19, 23].

## CONCLUSION

We conclude that chemical sphincterotomy with the use of topical 2% diltiazem may be considered as the first line treatment for chronic anal fissures, in spite of the higher rate of recurrence and the temporary anal incontinence. Lateral internal sphincterotomy should be reserved for the patients who have failed to respond to the initial chemical sphincterotomy.

## ACKNOWLEDGEMENT

We would like to thank all the consultant surgeons at the Vinaya Hospital and Research Centre, south Canara, for allowing us to analyze their cases. We are very grateful to Dr. Nanjesh and Dr. Tantry for their help with the statistical analysis. The authors confirm that there are no known conflicts of interest which are associated with this publication and that there has been no financial support for this work that could have influenced its outcome.

## REFERENCES

- Leong APK. The pharmacological treatment of anal fissures – A future role in the primary care. *Singapore Med J* 2003; 44(3): 136-37.
- Uwe W. Pharmacological sphincterotomy for chronic anal fissures with the use of the botulinum toxin A. *J Cutan Aesthet Surg*. 2008 Jul-Dec; 1(2): 58-63.
- Jensen SL. Diet and other risk factors for fissure-in-ano. A prospective case control study. *Dis Colon Rectum*. 1988 Oct; 31(10):770-73.
- Utzig MJ, Kroesen AJ, Buhr HJ. Concepts in the pathogenesis and the treatment of chronic anal fissures—a review of the literature. *The American Journal of Gastroenterology* 2003; 98: 968-74.
- Hisham MA. A comparative study on oral and topical nifedipine in the treatment of chronic anal fissures. *Sudanese Journal of Public Health* 2012 (Oct); 5(4).
- Jonas M, Scholefield JH. Anal fissures. *Gastroenterol Clin North Am* 2001; 30(1):167-81.
- Gupta PJ. The treatment of fissure in ano- revisited. *Afr Health Sci*. 2004 April; 4(1): 58-62.
- Golfam F, Golfam P, Khalaj A, Mortaz SSS. The effect of topical nifedipine in the treatment of chronic anal fissures. *Acta Medica Iranica* 2010; 48(5): 295-99.

- [9] Jonathan NL, John HS. A randomised, prospective, double-blind, placebo-controlled trial of glyceryl trinitrate ointment in the treatment of anal fissures. *The Lancet* 1997; 349:11-14.
- [10] Garcea G, Sutton C, Mansoori S, Lloyd T, Thomas M. The results following conservative lateral sphincterotomy for the treatment of chronic anal fissures. *Colorectal Disease* 2003(July); 5( 4): 311-14.
- [11] Dhawan S, Chopra S. Nonsurgical approaches for the treatment of anal fissures. *The American Journal of Gastroenterology* 2007; 102: 1312-21.
- [12] Cook TA, Brading AF, Mortensen NJ. The contractile properties of the ano-rectal smooth muscle. *Br J Surg* 1999; 86:70-75.
- [13] Haq Z, Rahman M, Chowdhury RA, Baten MA, Khatun M. Chemical sphincterotomy—the first line of treatment for chronic anal fissures. *Mymensingh Med J*. 2005 Jan; 14(1):88-90.
- [14] Carapeti EA, Kamm MA, Mc Donald PJ. A randomised controlled trial that showed that glyceryl trinitrate heals anal fissures, that higher doses are not more effective, and that there is a high recurrence rate. *GUT* 1999; 44:727-30.
- [15] Zuberi BF, Rajput MR, Abro H, Shaikh SA. A randomised trial of the glyceryl trinitrate ointment and the nitroglycerin patch in the healing of anal fissures. *Int J Colorectal Dis* 2000; 15:243-45.
- [16] Carapeti EA, Kamm MA, Evans BK, Phillips RKS. Topical diltiazem and bethanechol decrease the anal sphincter pressure without side effects. *Gut* 1999; 45:719-22.
- [17] Lund JN, Scholefield JH. A randomised, prospective, double-blind, placebo-controlled trial of glyceryl trinitrate ointment in the treatment of anal fissures. *Lancet* 1997; 349:11-14.
- [18] Kennedy ML, Sowter S, Nguyen H, Lubowski DZ. Glyceryl trinitrate ointment for the treatment of chronic anal fissures: the results of a placebo-controlled trial and a long term follow-up. *Dis Colon Rectum* 1999; 42(8):1000-06.
- [19] Knight JS, Birks M, Farouk R. The topical diltiazem ointment in the treatment of chronic anal fissures. *Br J Surg*. 2001; 88(4):553-56.
- [20] Carapeti EA, Kamm MA, Phillips RKS. Topical diltiazem and bethanechol decrease the anal sphincter pressure and heal anal fissures without side effects. *Dis Colon Rectum* 2000; 43:1359-62.
- [21] Antropoli C, Perrotti P, Rubino M, Martino A, De Stefano G, Migliore G, et al. Nifedipine for local use in the conservative treatment of anal fissures: the preliminary results of a multicentre study. *Dis Colon Rectum* 1999; 42(8):1011-15.
- [22] Perrotti P, Bove A, Antropoli C, Molino D, Antropoli M, Balzano A, et al. Topical nifedipine with lidocaine ointment vs. active control for the treatment of chronic anal fissures: the results of a prospective, randomized, double-blind study. *Dis Colon Rectum* 2002; 45(11): 1468-75.
- [23] Kocher HM, Steward M, Leather AJ, Cullen PT. A randomised clinical trial which assessed the side-effects of glyceryl trinitrate and diltiazem hydrochloride in the treatment of chronic anal fissures. *Br J Surg* 2002; 89:413-17.

**AUTHOR(S):**

1. Dr. Rithin Suvarna
2. Dr. Panchami
3. Dr. Guruprasad Rai D.

**PARTICULARS OF CONTRIBUTORS:**

1. Associate Professor, AJIMS, Mangalore, India.
2. Assistant Professor, FMMS, Mangalore, India.
3. Assistant Professor, AJIMS, Mangalore, India.

**NAME, ADDRESS, E-MAIL ID OF THE CORRESPONDING AUTHOR:**

Dr. Rithin Suvarna  
Associate Professor  
AJIMS, Mangalore, India.  
Phone: 9886203235  
E-mail: dr.rithinsuvarna@gmail.com

**FINANCIAL OR OTHER COMPETING INTERESTS:**

None.

Date of Submission: **Apr 09, 2012**  
Date of Peer Review: **May 01, 2012**  
Date of Acceptance: **Jun 25, 2012**  
Date of Publishing: **Aug 10, 2012**